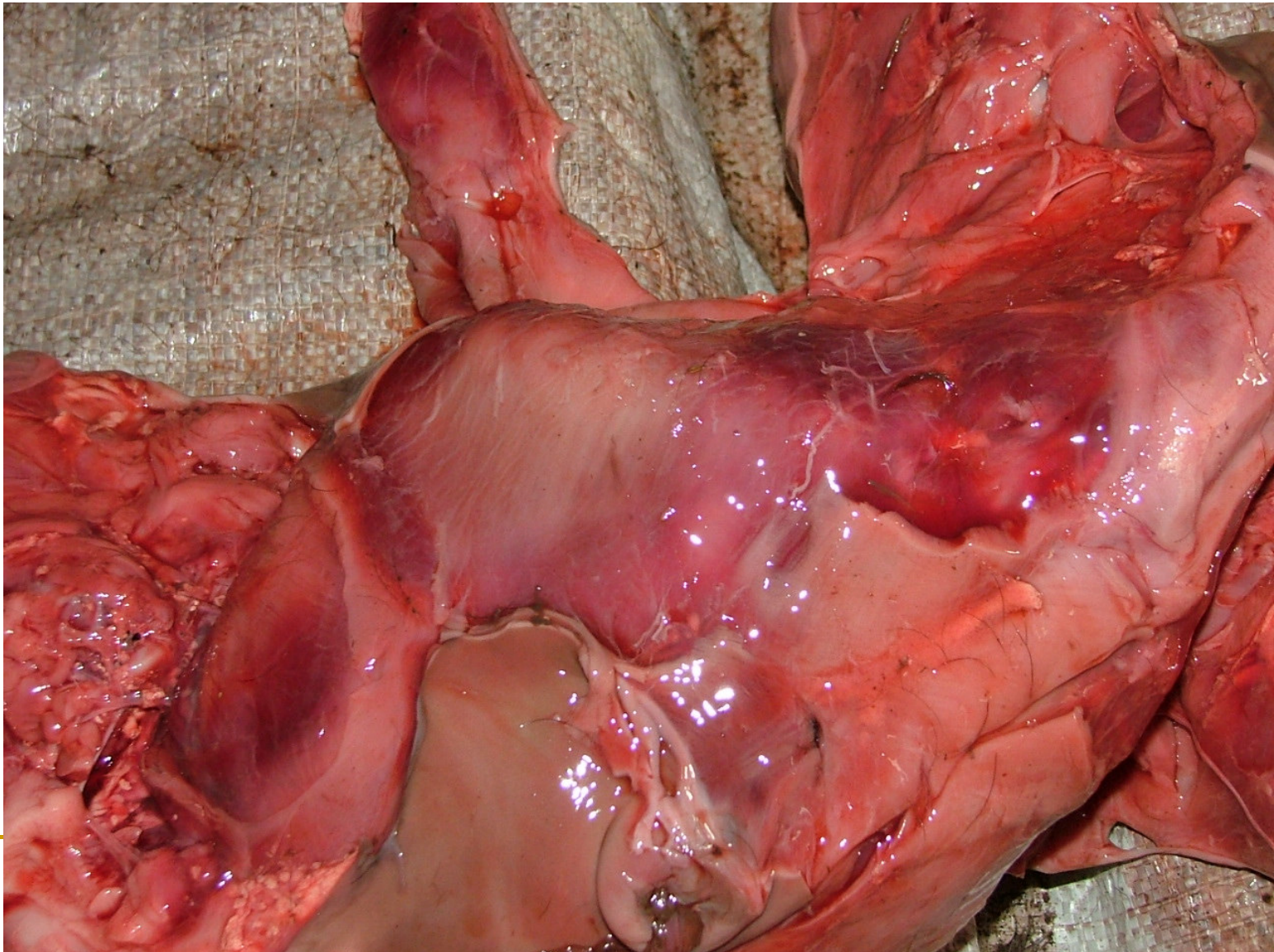


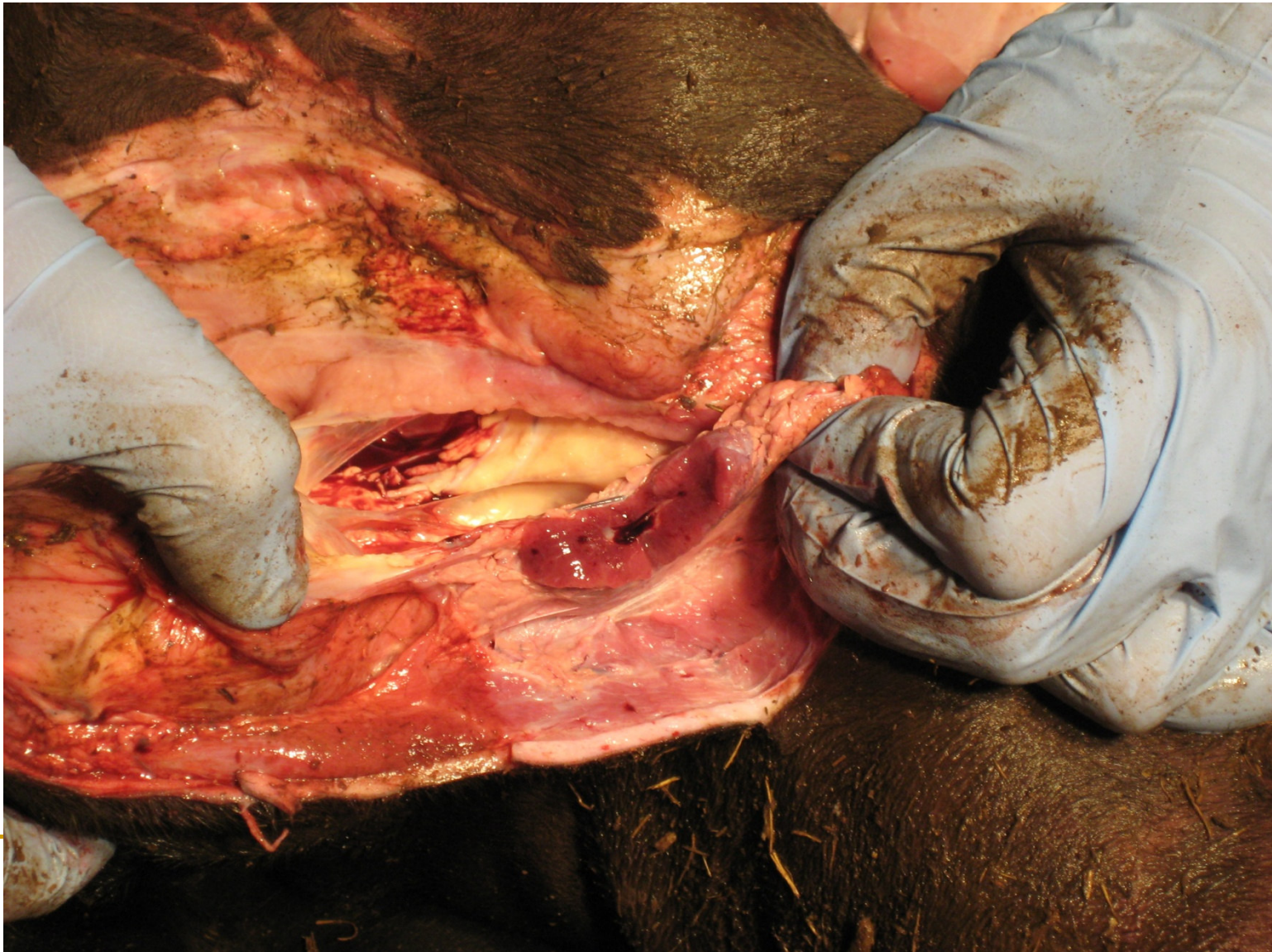
The Pathogenesis, Clinical Diagnosis and Differential Diagnosis of Rift Valley Fever in Animals- Abortions in Captive African Buffalo

Female fetus +/- 4 months; widespread s/c sugillations



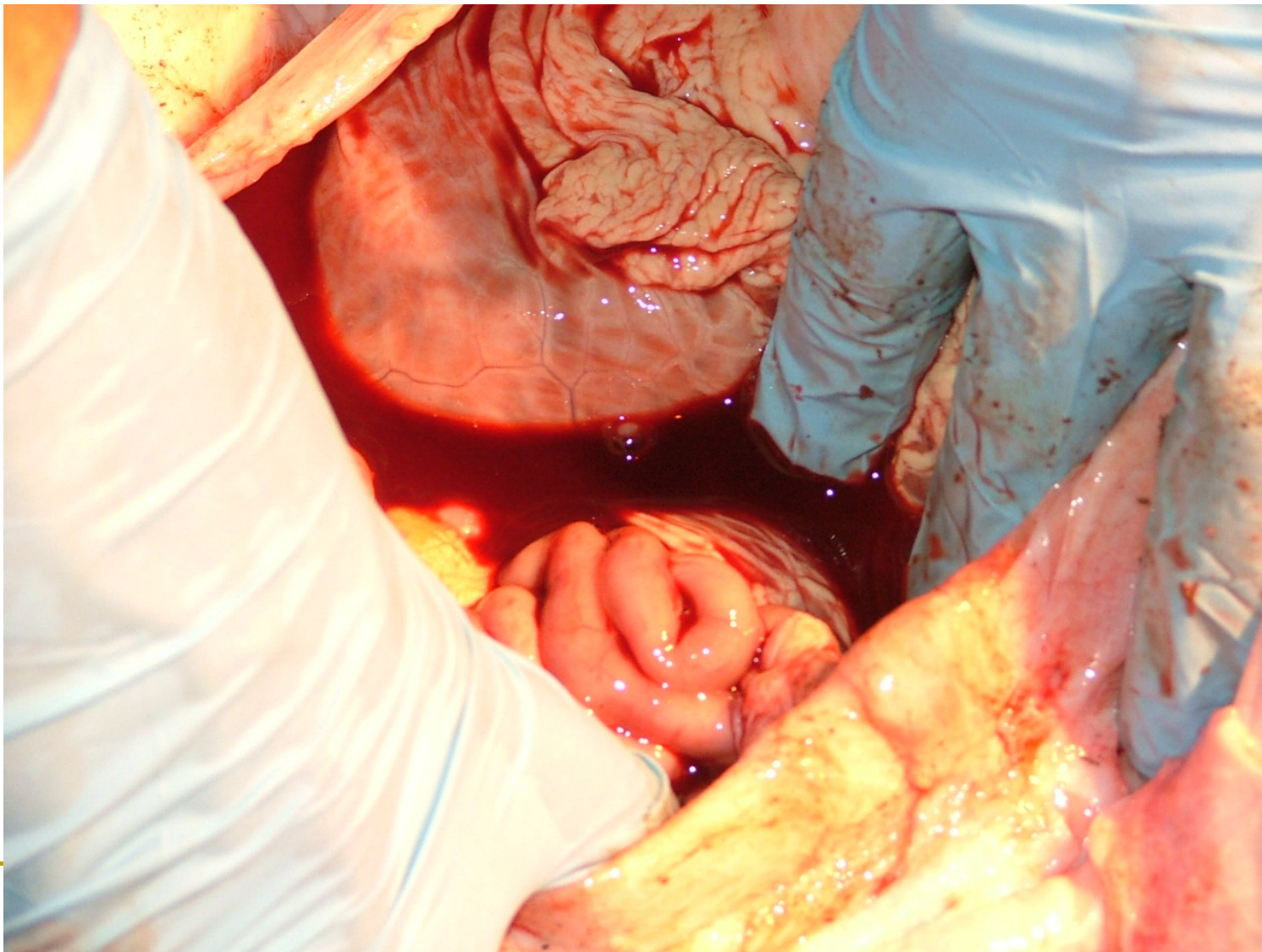
The Pathogenesis, Clinical Diagnosis and Differential Diagnosis of Rift Valley Fever in Animals- Abortions in Captive African Buffalo

Female stillbirth, dystocia; edema and haemorrhages in prescapular Ln



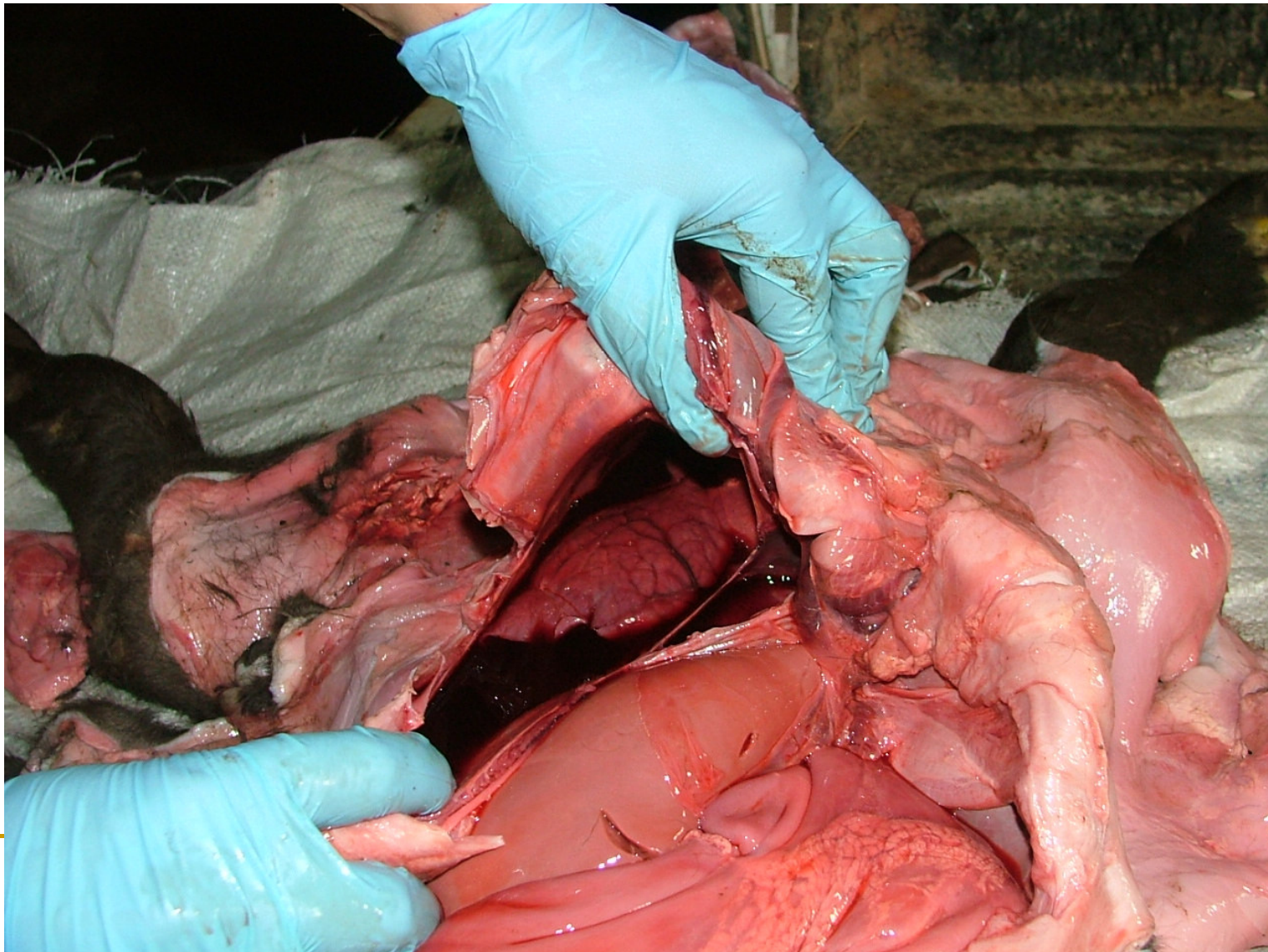
The Pathogenesis, Clinical Diagnosis and Differential Diagnosis of Rift Valley Fever in Animals- Abortions in Captive African Buffalo

Female stillbirth, dystocia; hemoperitoneum



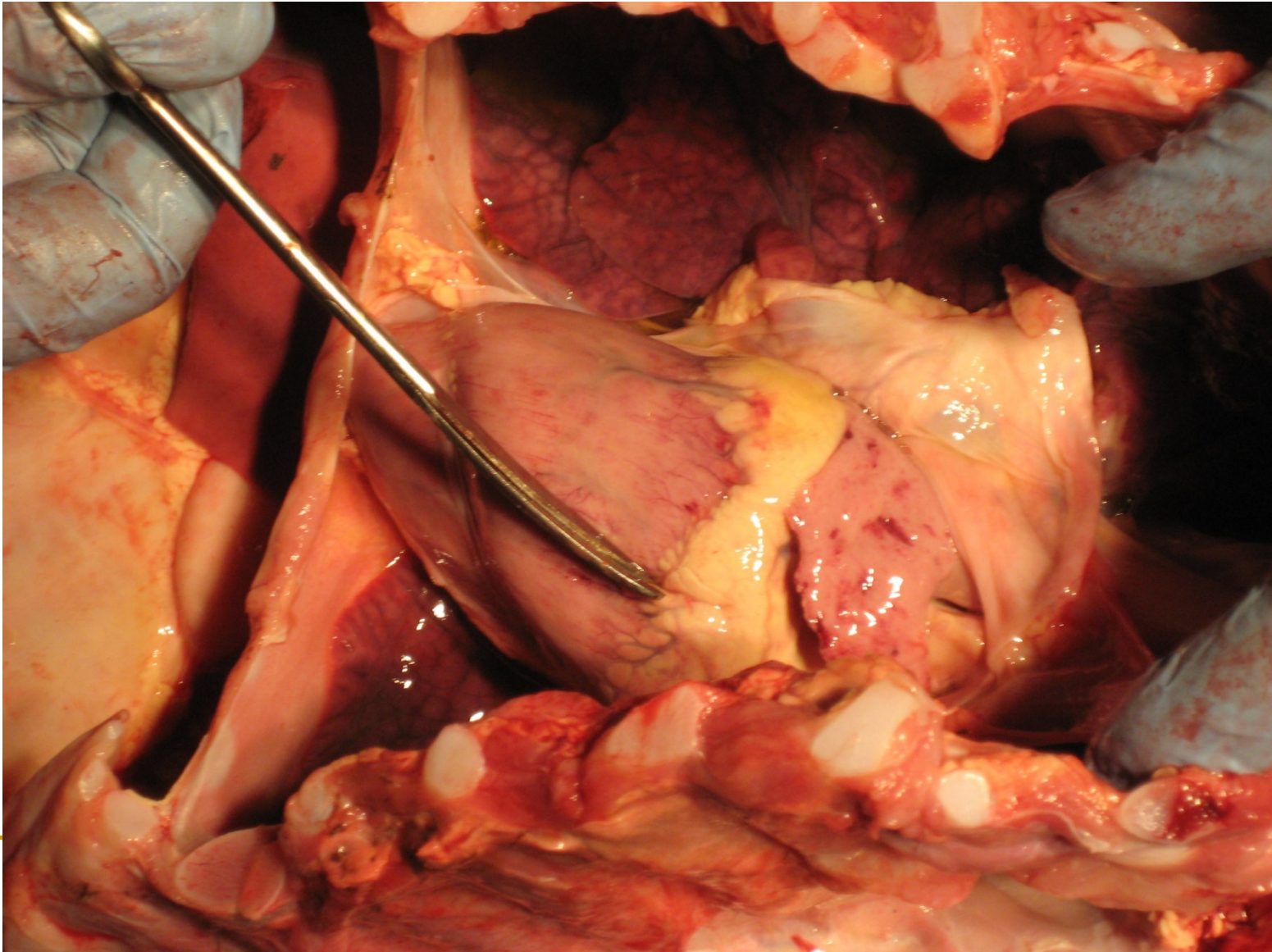
The Pathogenesis, Clinical Diagnosis and Differential Diagnosis of Rift Valley Fever in Animals- Abortions in Captive African Buffalo

Male fetus +/- 10 months; hemothorax, lung edema



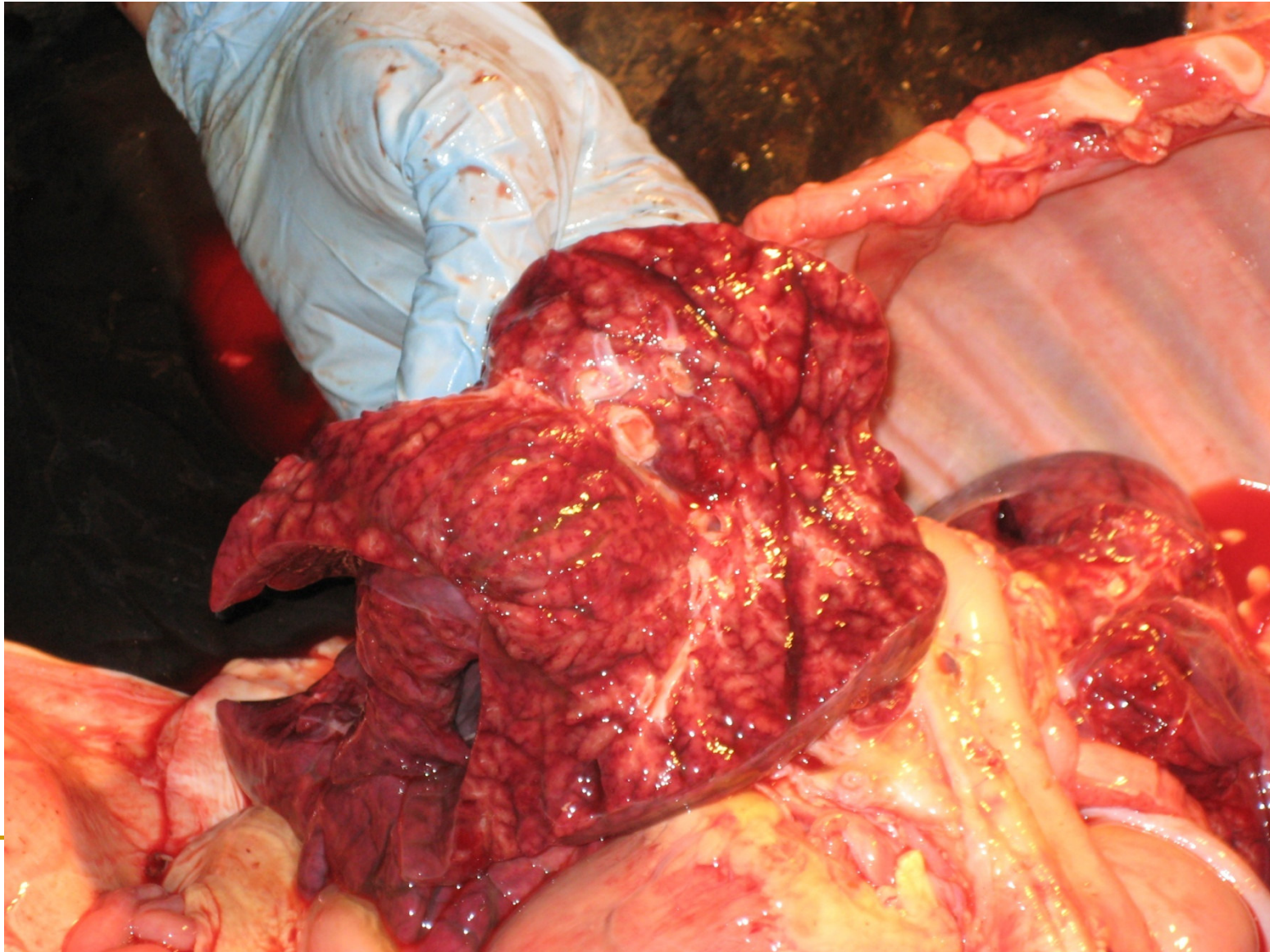The Pathogenesis, Clinical Diagnosis and Differential Diagnosis of Rift Valley Fever in Animals- Abortions in Captive African Buffalo

Female stillbirth, dystocia; epicardial hemorrhages



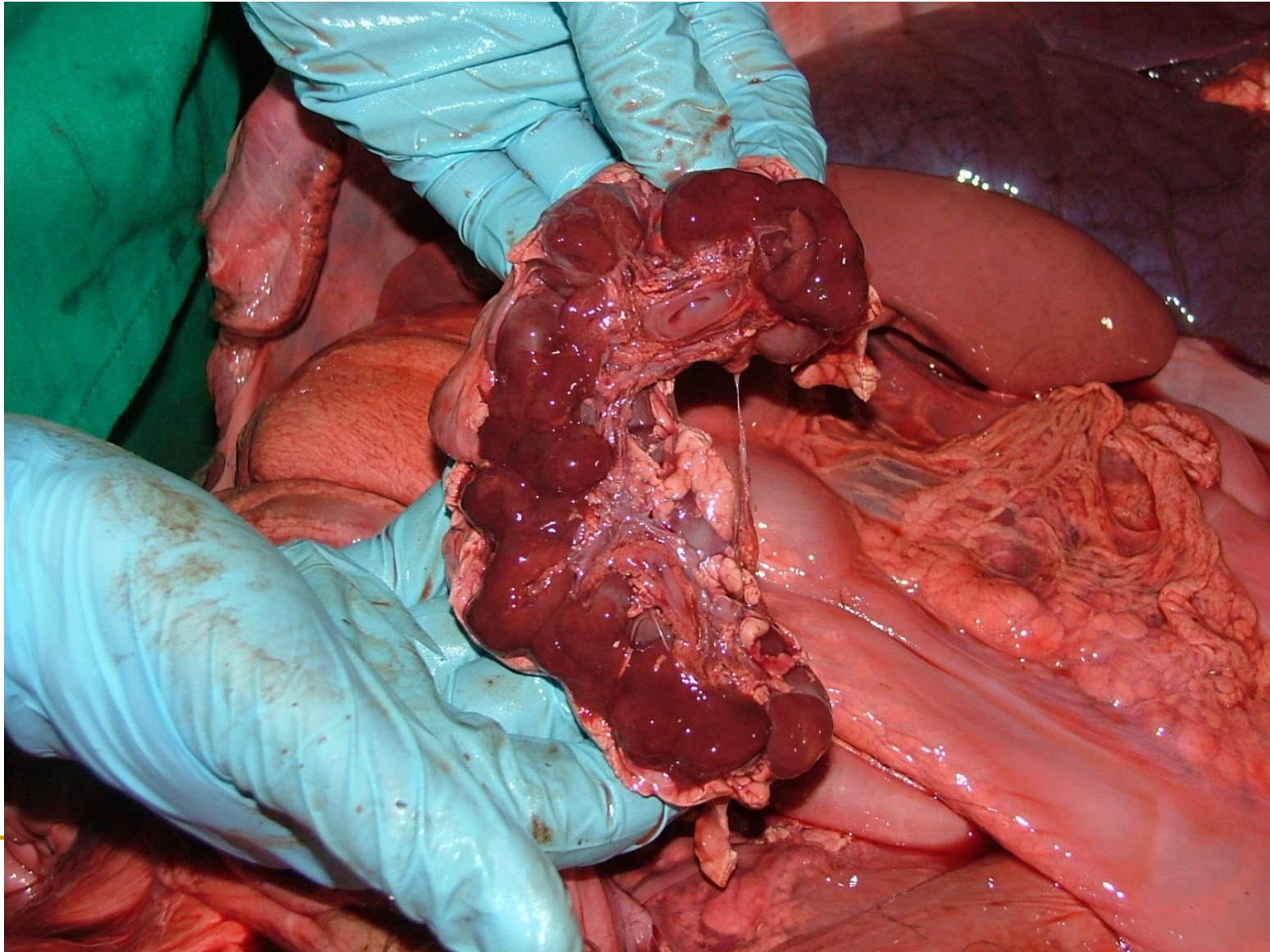
The Pathogenesis, Clinical Diagnosis and Differential Diagnosis of Rift Valley Fever in Animals- Abortions in Captive African Buffalo

Female stillbirth, dystocia; lung congestion, edema and hemorrhages



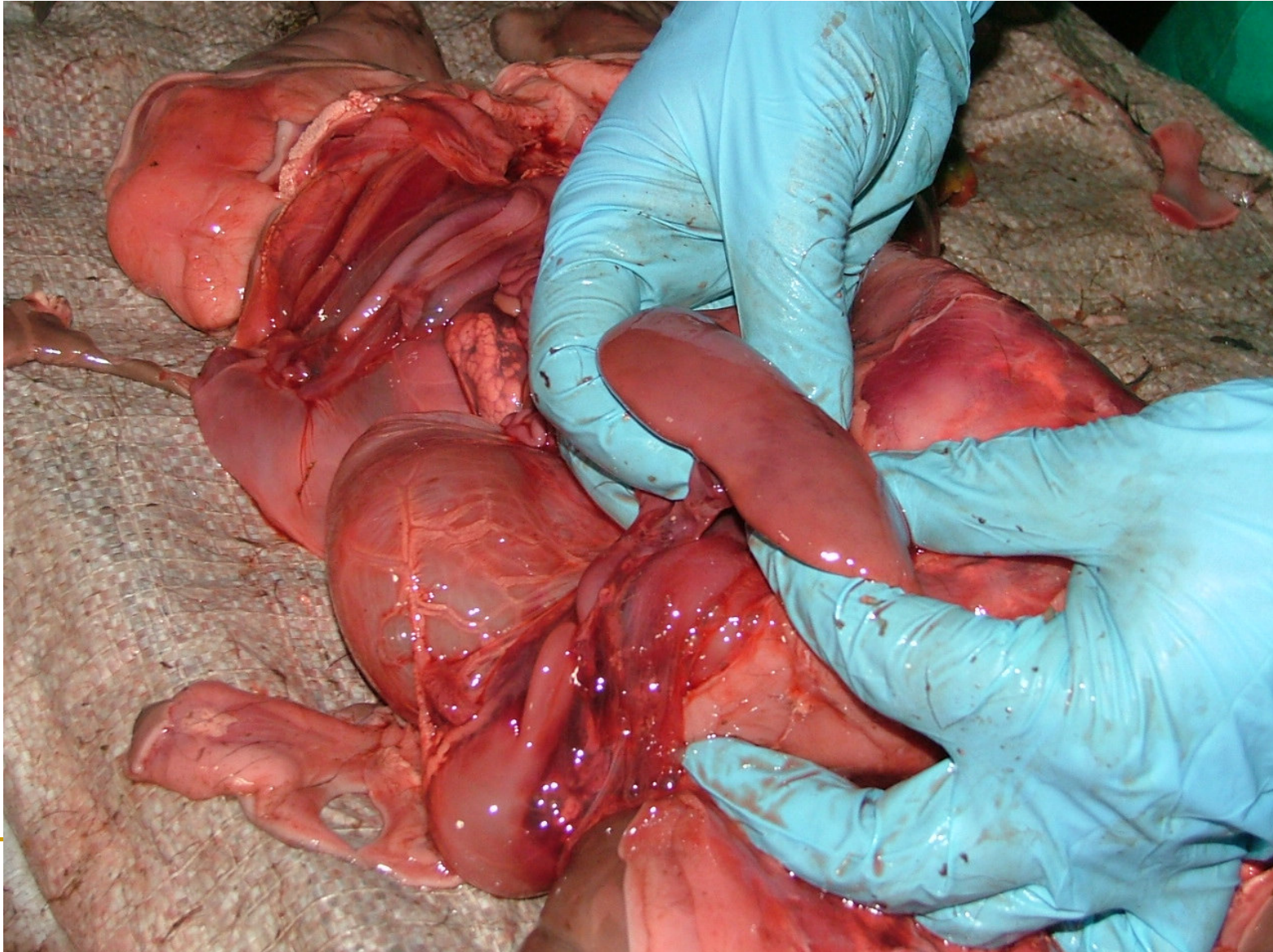The Pathogenesis, Clinical Diagnosis and Differential Diagnosis of Rift Valley Fever in Animals- Abortions in Captive African Buffalo

Female fetus +/- 11 months; pulpy, hemorrhagic kidneys



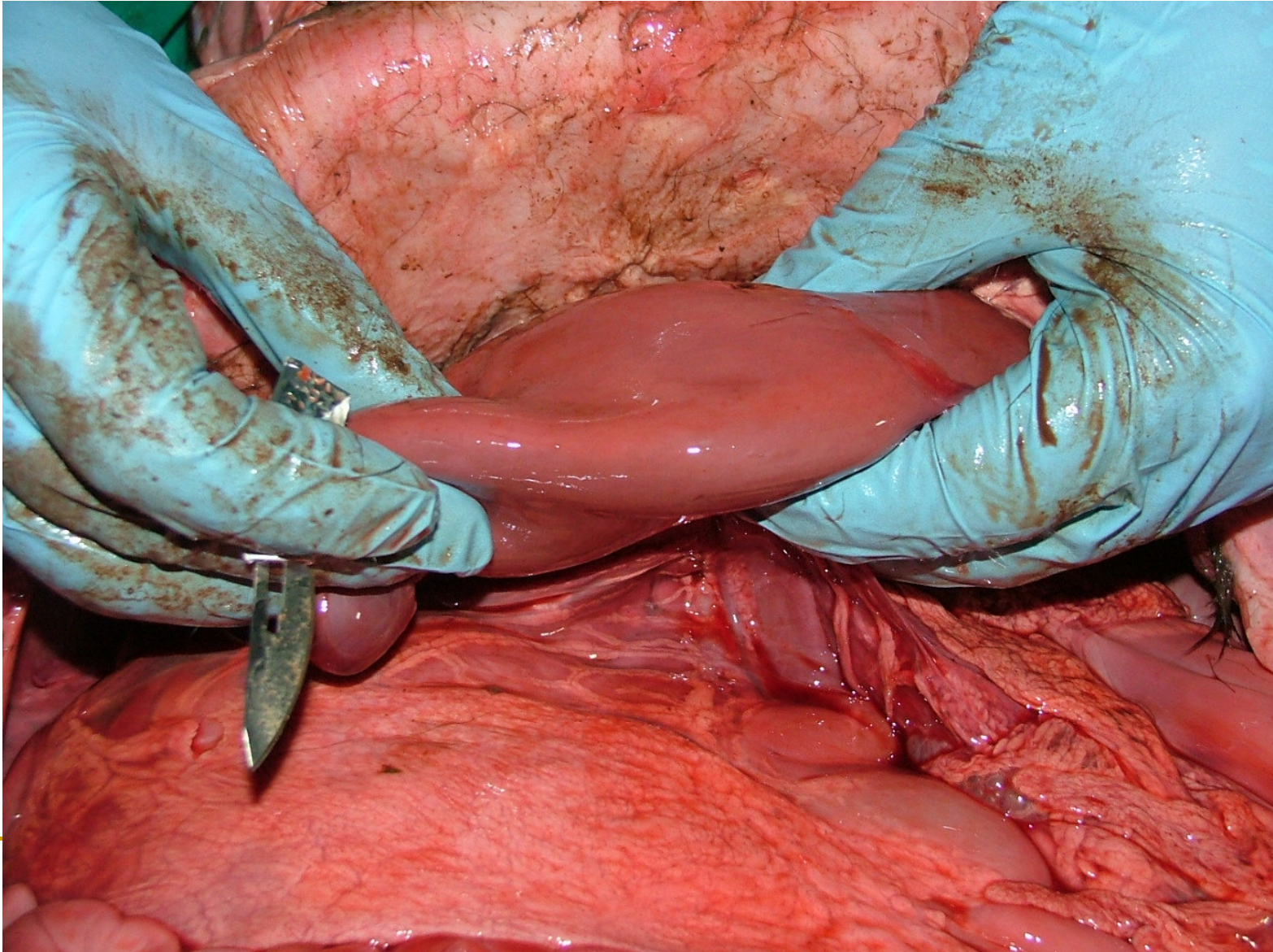
The Pathogenesis, Clinical Diagnosis and Differential Diagnosis of Rift Valley Fever in Animals- Abortions in Captive African Buffalo

Female fetus +/- 4 months; hepatomegaly, subcapsular hemorrhages



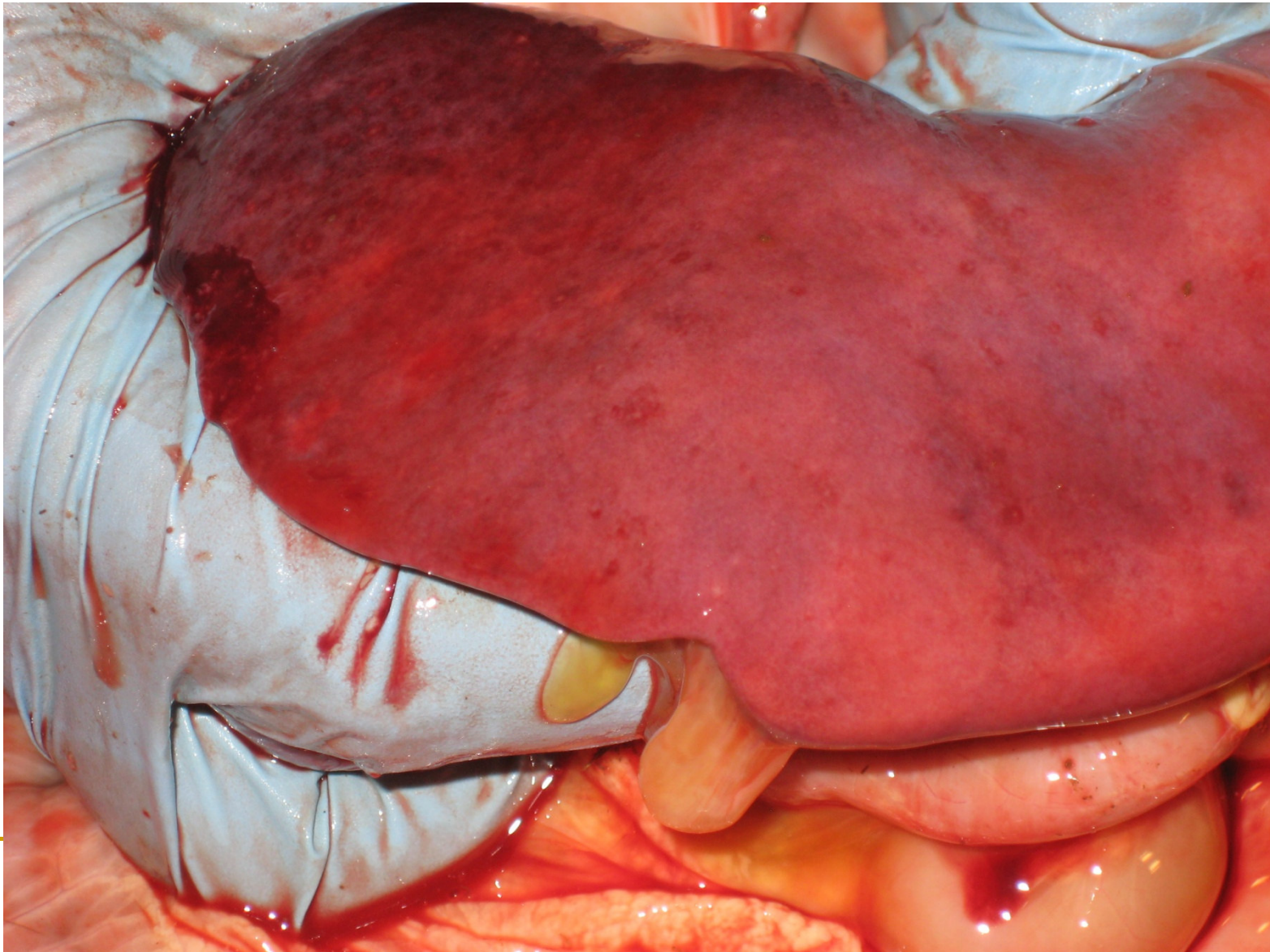
The Pathogenesis, Clinical Diagnosis and Differential Diagnosis of Rift Valley Fever in Animals- Abortions in Captive African Buffalo

Female fetus +/- 11 months; hepatomegaly



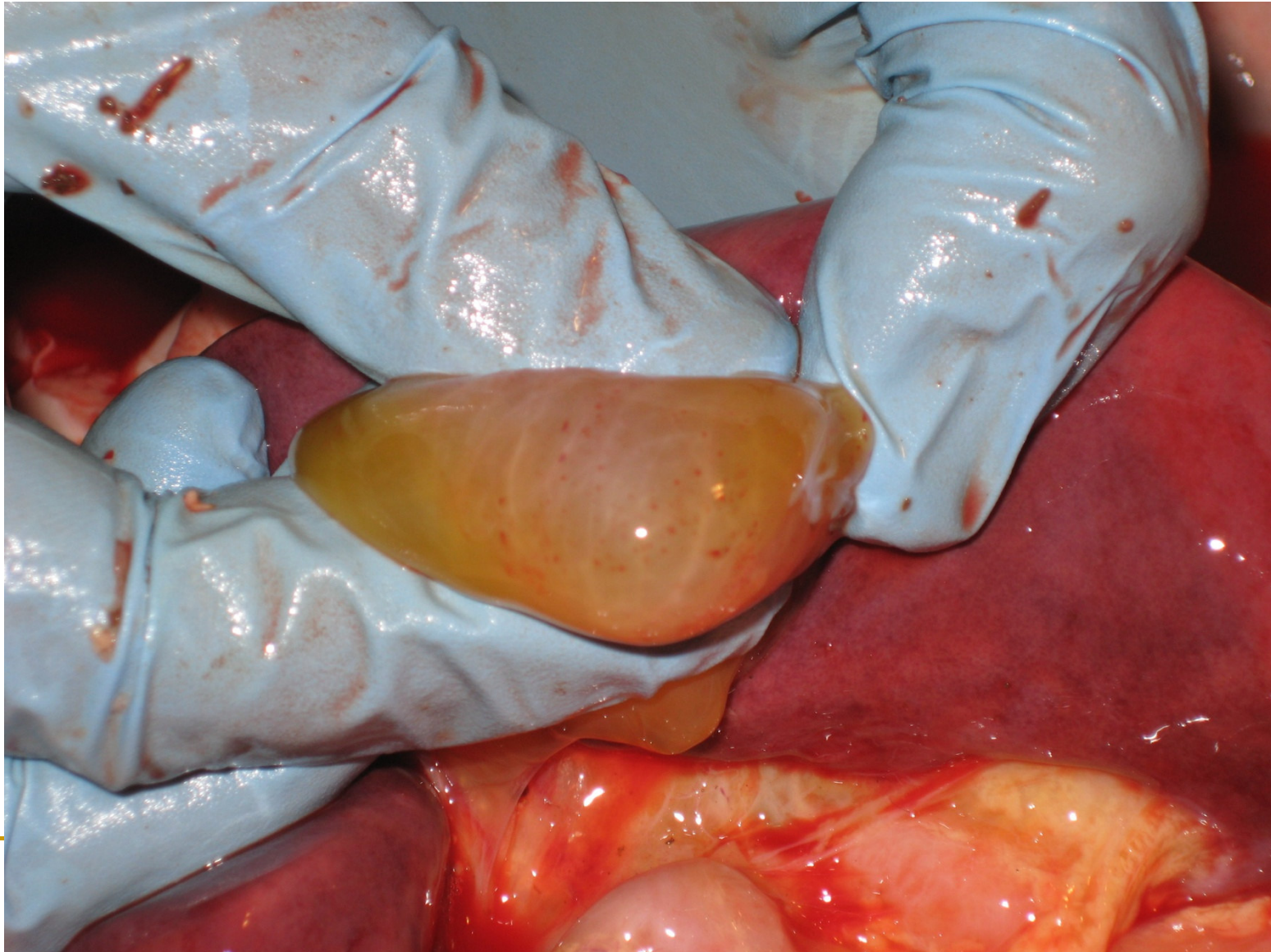The Pathogenesis, Clinical Diagnosis and Differential Diagnosis of Rift Valley Fever in Animals- Abortions in Captive African Buffalo

Female stillbirth, dystocia; hemorrhages of enlarged liver



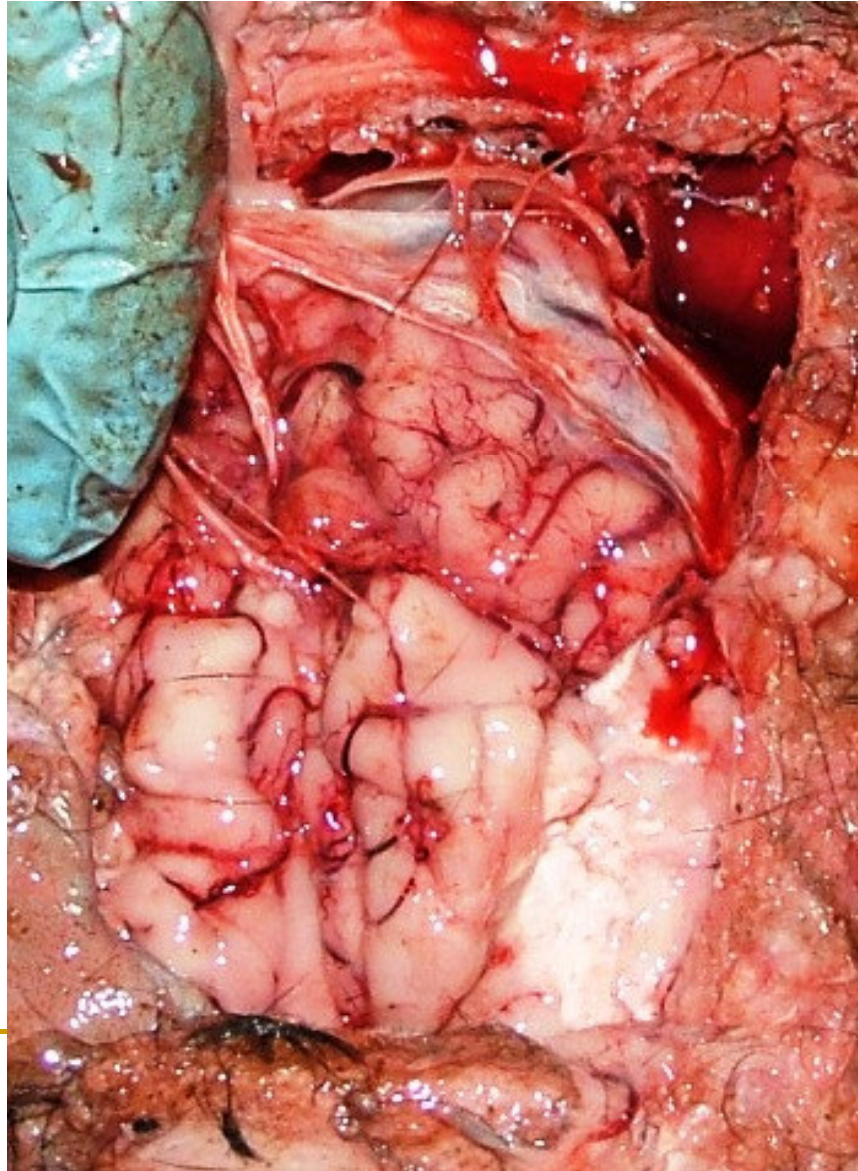
The Pathogenesis, Clinical Diagnosis and Differential Diagnosis of Rift Valley Fever in Animals- Abortions in Captive African Buffalo

Female stillbirth, dystocia; petechiation and edema of gallbladder wall



The Pathogenesis, Clinical Diagnosis and Differential Diagnosis of Rift Valley Fever in Animals- Abortions in Captive African Buffalo

Female fetus +/- 11 months; cerebral congestion



The Pathogenesis, Clinical Diagnosis and Differential Diagnosis of Rift Valley Fever in Animals- Abortions in Captive African Buffalo

Diagnostic challenges

- Can also be outside the typical accompanying seasonal and climatic factors
- Difficulties in diagnosing isolated cases
- Aspects of biosafety for owners/handlers and veterinary personnel when handling infected material !

Chance: Zoonotic potential and respective awareness measures can improve cooperation with animal owners, control of diseases, primary health care of livestock and thus better production output.

Acknowledgements (a.o.) :

- Drs van Rensburg and Kotze for assistance with PMs/sampling, photographic documentation and supply of further data
 - Dr BJA Du Plessis for providing contents of his talk “NKOMAZI RIFT VALLEY FEVER OUTBREAK 2008”, presented on 13/02/2008 during RVF Information Session Service at the Mpumalanga Veterinary Services head office, for inclusion in this presentation ; as well as data from INFORMATION BULLETIN NO. 3 : 10 June 2008 “RIFT VALLEY FEVER OUTBREAKS, EHLANZENI DISTRICT, MPUMALANGA PROVINCE”
 - OVI personnel for testing and follow ups
 - Prof. R Swanepole (NCID) for providing advise
 - OIE, CDVS MP, VS RSA for invitation and facilitation of participation
-